



# 3D - RECONSTRUCTION OF THE HUMAN VISIBLE LYMPH NODES (THE LYMPHATIC SYSTEM 400 YEARS FROM ASELLI'S DISCOVERY)



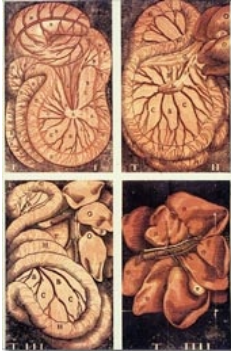
Ion Christian Kiricuta\*, Sharif Qatarneh\*\*, Anders Brahme\*\*

\*Institute of Radiation Oncology, St. Vincenz-Hospital, Limburg, Germany,

\*\*Department of Medical Radiation Physics, Karolinska Institute and Stockholm University, Stockholm, Sweden

## Background:

Since the description of the lacteals in a recently fed dog by Aselli 400 years before, the progress in imaging methods made possible the identification of the lymph nodes in the visible human optical dataset (VHDS).



Aselli's tables of the chyloferous vessels, the first ones printed in colour

## Purpose:

To present the 3-D reconstruction of the optical visible lymph nodes identified in an "undisturbed" anatomy in the VHDS of the male.

## Material and Methods:

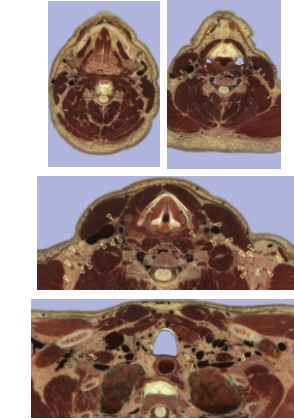
The dataset from the visible human male was studied. The male whose body was used as visible human was 38 years old at the time of death. The cadaver was perfused with 1% formalin and anticoagulant. Optical anatomic microtome produced slices at 1 mm interval and with a resolution of 2.8 pixels per mm were carefully examined. The head and neck, axilla, chest, abdomen, pelvis and inguinal region was investigated. New data on the location of normal size lymph nodes in anatomical optical microtome sections were acquired.

## Results:

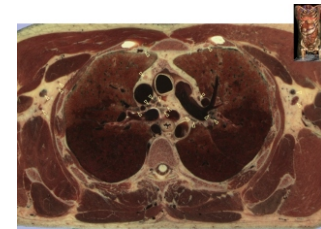
"Invisible" nodes were identified, i.e., normal size lymph nodes with diameters of less than 3 mm which remain "invisible" for imaging methods such as CT or MRI. The 3-D reconstruction of the optically identified lymph nodes of the head and neck, axilla, chest, abdomen, pelvis and inguinal region was possible. Around 900 lymph nodes could be identified.

## Conclusions:

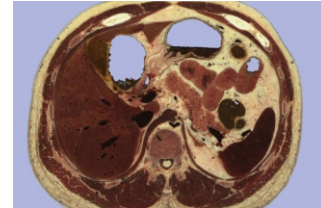
New data on the location, number and size of lymph nodes based on the VHDS were acquired. A 3D representation of all the identified lymph nodes was performed. These data are of importance for definition of quality of the pathological examination and in training of surgical procedures and the target volume delineation in radiation oncology.



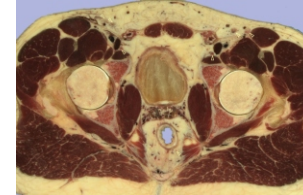
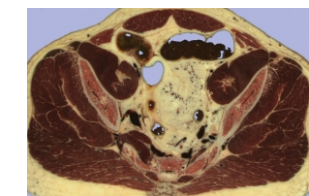
The Head and Neck Lymph Nodes



Axillary and Mediastinal Lymph Nodes

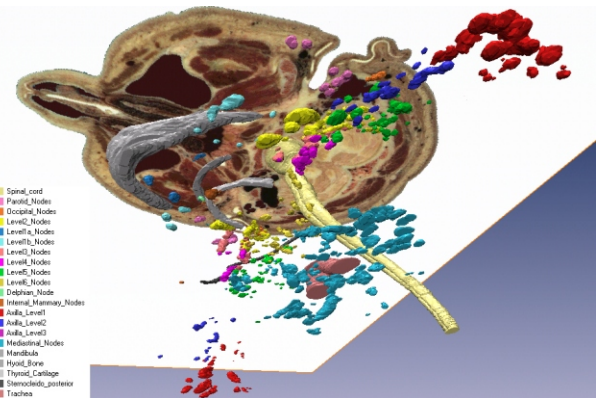


Upper Abdominal Lymph Nodes

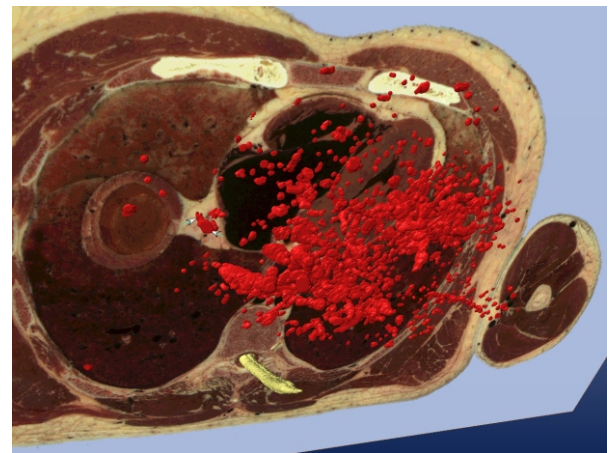


Pelvic, Mesorectal and Inguinal Lymph Nodes

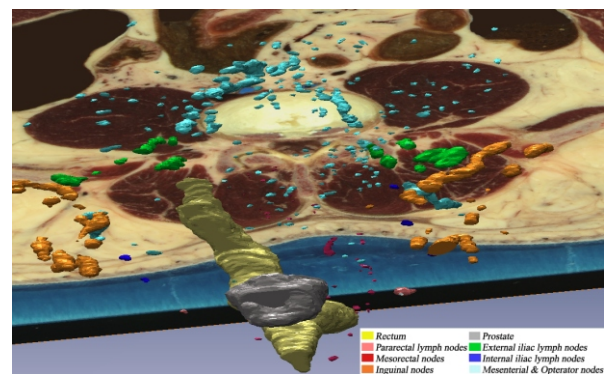
## References:



3D - Reconstruction of the Supradiaphragmatic Lymph Nodes in the Visible Human Male Dataset



3D - Reconstruction of the Abdominal Lymph Nodes in the Visible Human Male Dataset



3D - Reconstruction of the Pelvic, Mesenteric and Inguinal Lymph Nodes in the Visible Human Male Dataset

